THE JOURNAL OF PROSTHETIC DENTISTRY

CLINICAL REPORT

# Forced orthodontic extrusion for an apparently hopeless anterior tooth by using a simplified approach

Álvaro Ferrando Cascales, DDS, PhD,[a] Raúl Ferrando Cascales, DDS, PhD,[b] José Lacal Luján, DDS, PhD,[c] and Francesc Abella Sans, DDS, PhD[d]

## ABSTRACT

When restoring severely compromised teeth, respecting the supracrestal tissue attachment and retaining the most coronal and radicular tooth structure is essential to achieving a sufficient ferrule. Forced orthodontic extrusion is a minimally invasive method that allows hard- and soft-tissue conservation. This article describes the treatment of a severely damaged maxillary central incisor that was managed by using a simplified orthodontic extrusion method with intracoronal elastic and metal ligatures applied through a palatal bar and followed by the biologically oriented preparation technique (BOPT). This orthodontic procedure reduces a forward clockwise advance during vertical extrusion, thus maintaining the buccal bone plate. (J Prosthet Dent 2022;■:■-■)

Restoring teeth with limited coronal tooth structure and defects at the subcrestal level is challenging.[1] Caries, subgingival tooth preparation, root perforation, resorption, or a fracture that penetrates the gingival sulcus is typically associated with nonrestorable teeth unless the restoration margins are prevented from encroaching on the biologic width (BW).[2,3] The supracrestal tissue attachment (STA), which recently replaced the term BW, has been defined as the histological structure of the junctional epithelium and supracrestal connective tissue attachment.[4] There is a broad consensus that the STA must be left intact regardless of the type of restoration performed.[5] Invasion of the STA may produce gingivitis or periodontitis, attachment loss, periodontal pockets, bleeding, suppuration, swelling, and gingival recession.[6-8]

Unlike traditional prosthetic restorations, adhesives and composite resins allow a more conservative approach to managing severely compromised teeth by reducing invasiveness. Nevertheless, a minimum distance between the restoration margin and the bone level should be maintained, specifically at the level of the junctional epithelium.[9-11] A distance of at least 3 mm has been recommended to avoid impingement on the coronal attachment of the periodontal connective tissue.[12-15] In the absence of tooth structure coronal to the alveolar bone, a ferrule can be provided by using surgical crown lengthening, intra-alveolar transplantation, or orthodontic extrusion.[16,17]

Orthodontic extrusion, also known as forced orthodontic extrusion, has been defined as the forced movement of teeth in the axial plane to modify the tooth position and/or induce changes in the surrounding alveolar bone and soft tissue.[18] This versatile and minimally invasive technique can be used as an alternative to surgical crown lengthening and intra-alveolar transplantation.[18,19] In 1973, Heithersay[20] proposed using orthodontic extrusion for a therapeutic end other than orthodontic tooth alignment, and Ingber[21,22] described the use of orthodontic extrusion to treat insufficient clinical crown length for adequate ferrule, which otherwise would require either surgical crown lengthening or extraction as the definitive treatment. This crown lengthening technique was improved by Pontoriero et al[23] with the introduction of supracrestal fiberotomy to impede the simultaneous migration of the periodontium and the extruded tooth.

[a]Postgraduate in Dentistry San Antonio de Murcia Catholic University (UCAM) Murcia, Spain.
[b]Associate Professor, Faculty of Health Sciences, San Antonio de Murcia Catholic University (UCAM), Murcia, Spain and Director of the Master with Exclusive Dedication in Orthodontics and Dentofacial Orthopedics (UCAM).
[c]Associate Professor, Department of Oral Surgery, University of Murcia, Murcia, Spain.
[d]Director, Department of Restorative Dentistry and Endodontics, School of Dentistry, Universitat Internacional de Catalunya, Barcelona, Spain.

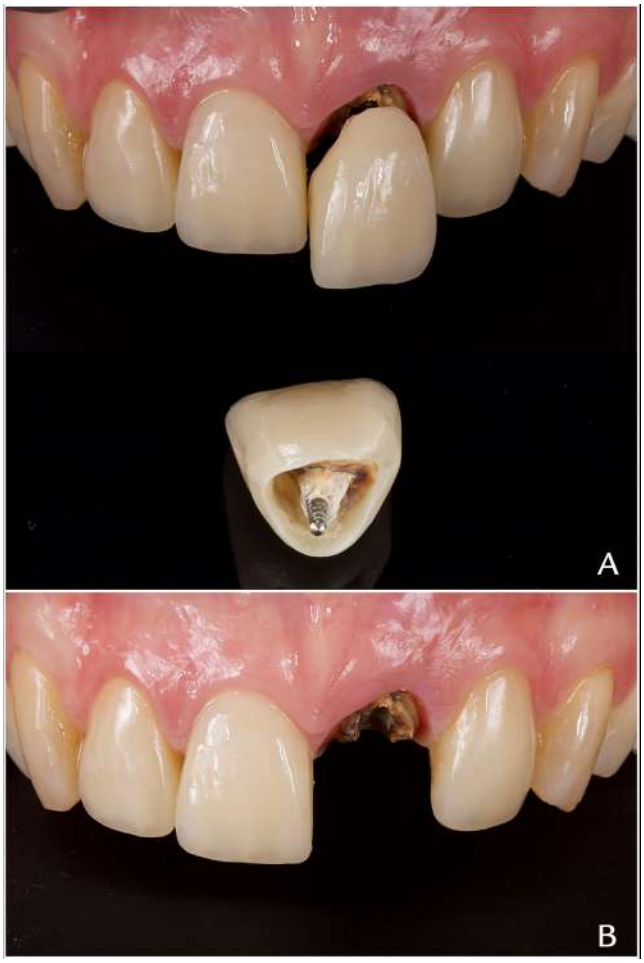


**Figure 1.** Debonding of zirconia crown on maxillary left central incisor from retention loss. A, Clinical detail of restorative failure. B, Preoperative clinical situation. Note extension of subgingival carious lesion and lack of adequate ferrule.

This clinical report presents the treatment of a severely damaged maxillary central incisor managed by using a simplified orthodontic extrusion method with intracoronal elastic and metal ligatures applied through a palatal bar and followed by a biologically oriented preparation technique (BOPT).

## CLINICAL REPORT

A 55-year-old woman was referred to a private practice for the treatment of a maxillary left central incisor. She reported multiple debondings of a zirconia crown on the tooth (Fig. 1A). Her medical history was noncontributory, and she was not a smoker. The remaining tooth had a subgingival carious lesion and insufficient ferrule (Fig. 1B). Pathologic mobility was not observed, and probing depth ranged between 1.5 and 2 mm. The tooth was asymptomatic to percussion and palpation, and the gingival margin of the tooth was at the same level as the maxillary right central incisor. Endodontic retreatment was not indicated despite possible coronal leakage, as the radiographic examination showed a well-obturated root canal and no periapical lesion (Fig. 2A). After discussing various treatment options, an interdisciplinary approach based on forced orthodontic extrusion was planned.

Under local anesthesia, the carious dentin was removed with a tungsten carbide bur (H1.204.014; Komet). The operative field was isolated with the aid of a barrier (OptraDam; Ivoclar AG) and polytetrafluoroethylene (PTFE) tape placed as a displacement cord within the sulcus (Fig. 2B). A fiber post (Blue X-Post #3; Dentsply Sirona) was marked, reduced to an appropriate length with a high-speed diamond rotary instrument under water-cooling, and airborne-particle abraded (AquaCare TWIN; Velopex) with 29-μm aluminum-oxide ($Al_2O_3$) particles (AquaAbrasion; Velopex) for 5 seconds (Fig. 2C). Particles were removed with an air syringe for 5 seconds, and the post surface was cleaned with 95% isopropyl alcohol and wetted with a modeling liquid (GC Corp) (Fig. 2D). A layer of glycerin gel (K-Y lubricant gel; Johnson & Johnson) was placed inside the root canal to prevent to prevent retention of the individualized post with composite ( Ceram.x Spectra ST. LV-A2; Dentsply Sirona). Following a 10-second light-polymerizing cycle (SmartLite Pro; Dentsply Sirona), the post was removed, and composite polymerization was completed outside the mouth (Figs. 2E, 3A). The root canal dentin walls were airborne-particle abraded for a further 10 seconds with 50-μm $Al_2O_3$ (AquaCare; Velopex) and then cleaned with water for 20 seconds. The root walls were dried with absorbent paper points prior to bonding. The Prime&Bond active (Dentsply Sirona) in self-etch mode with Self Cure Activator (Dentsply Sirona) was applied inside the root canal walls for 20 seconds. Adhesive excess was removed with absorbent paper points, and the solvent was evaporated by a gentle air stream for 5 seconds. The composite resin surface of the post was then reactivated with the same protocol used previously but substituting the composite resin for the dentin adhesive applied to the tooth. Fiber post cementation and core buildup were done in 1 step by applying a dual-polymerizing composite resin (Core-X Flow; Dentsply Sirona) directly onto the surface of the fiber post and into the root canal (Fig. 3B-H).

Subsequently, the cervical region of the core buildup was transversely perforated with a high-speed diamond rotary instrument (859-010; Intensiv AS), taking care not to damage the fiber post (Fig. 4). Intracoronal elastic and metal ligatures were placed through the orifice created and were changed every week for 3 weeks.[24] A 1.5-mm-thick metal bar was adapted to the palatal surfaces of the anterior teeth to anchor the orthodontic traction and was cemented in maxillary canines and first premolars with a bulk-fill composite resin (SDR Flow; Dentsply Sirona) (Fig. 5). At each weekly appointment during the active

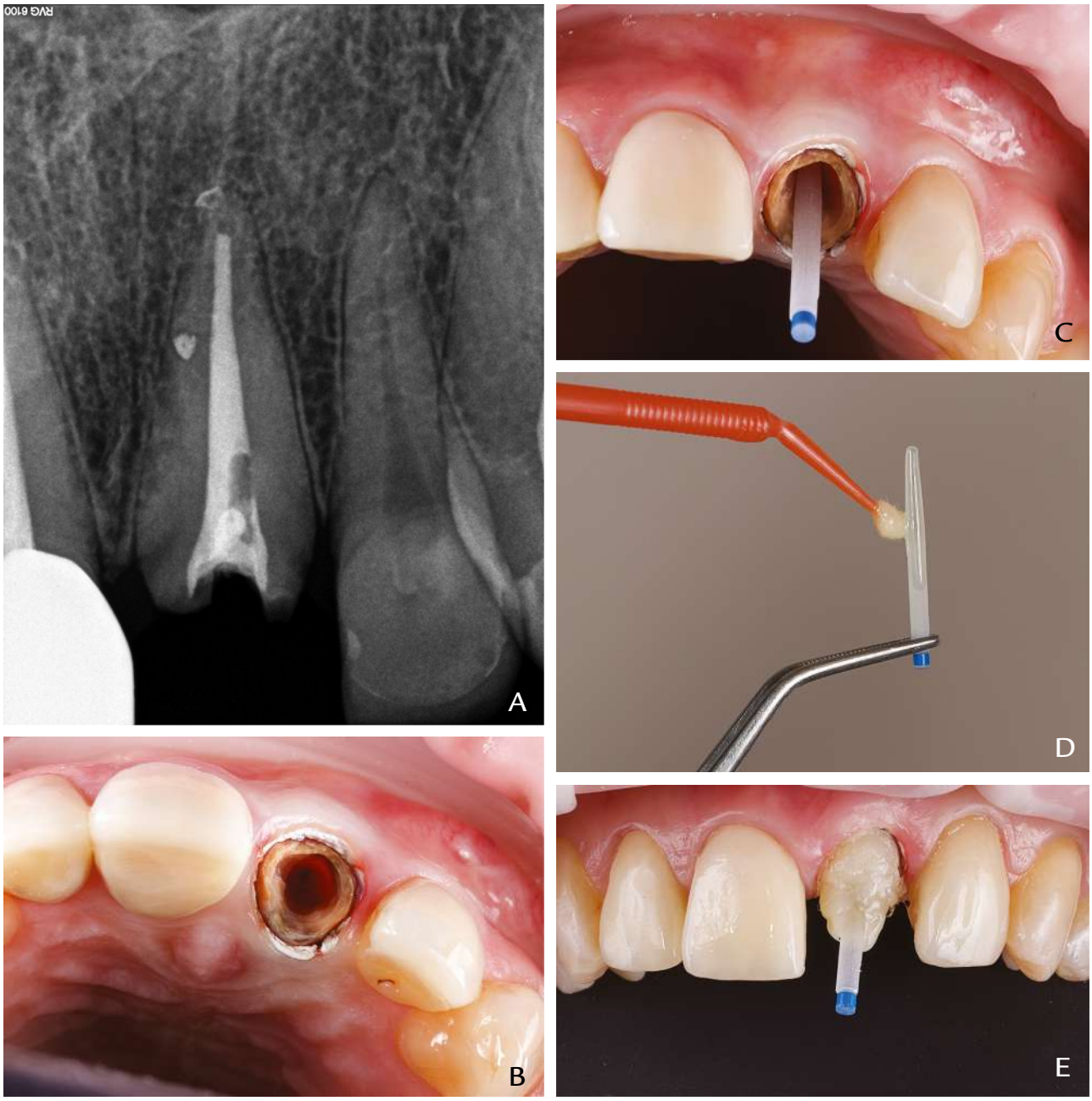


**Figure 2.** Step-by-step customization of glass fiber post. A, Initial periapical radiograph of nonrestorable tooth. B, Polytetrafluoroethylene (PTFE) tape placed as displacement cord within sulcus. C, Clinical evaluation of fiber post. D, Wetting of fiber post with modeling liquid (GC Corp). E, Placement of post into root canal by applying small quantity of universal composite resin.

extrusion period, circumferential supracrestal fiberotomy was performed to prevent coronal displacement of the gingival margin. An Essix-type removable retainer with a composite resin laminate veneer was fabricated as an interim restoration (Fig. 6A, 6B).

During the extrusion phase, periapical radiographs were made periodically to determine the extent of coronal displacement and the condition of the periodontal ligament. The procedure concluded when the root surface was sufficiently exposed to ensure an optimal ferrule for the prosthesis. This orthodontic technique provided a 2.0-mm extrusion, achieving a ferrule of about 3.0 mm buccally and palatally and 2.5 mm interproximally (Fig. 6C, 6D). After 6 weeks of retention, the tooth was vertically prepared by following the BOPT technique (Fig. 6E-H).[25] A computer-aided design and computer-aided manufacturing (CAD-CAM) composite resin crown (Structur CAD; VOCO GmbH) was relined and adapted to model the soft tissues and was seated with interim cement for 3 months to achieve a gingival

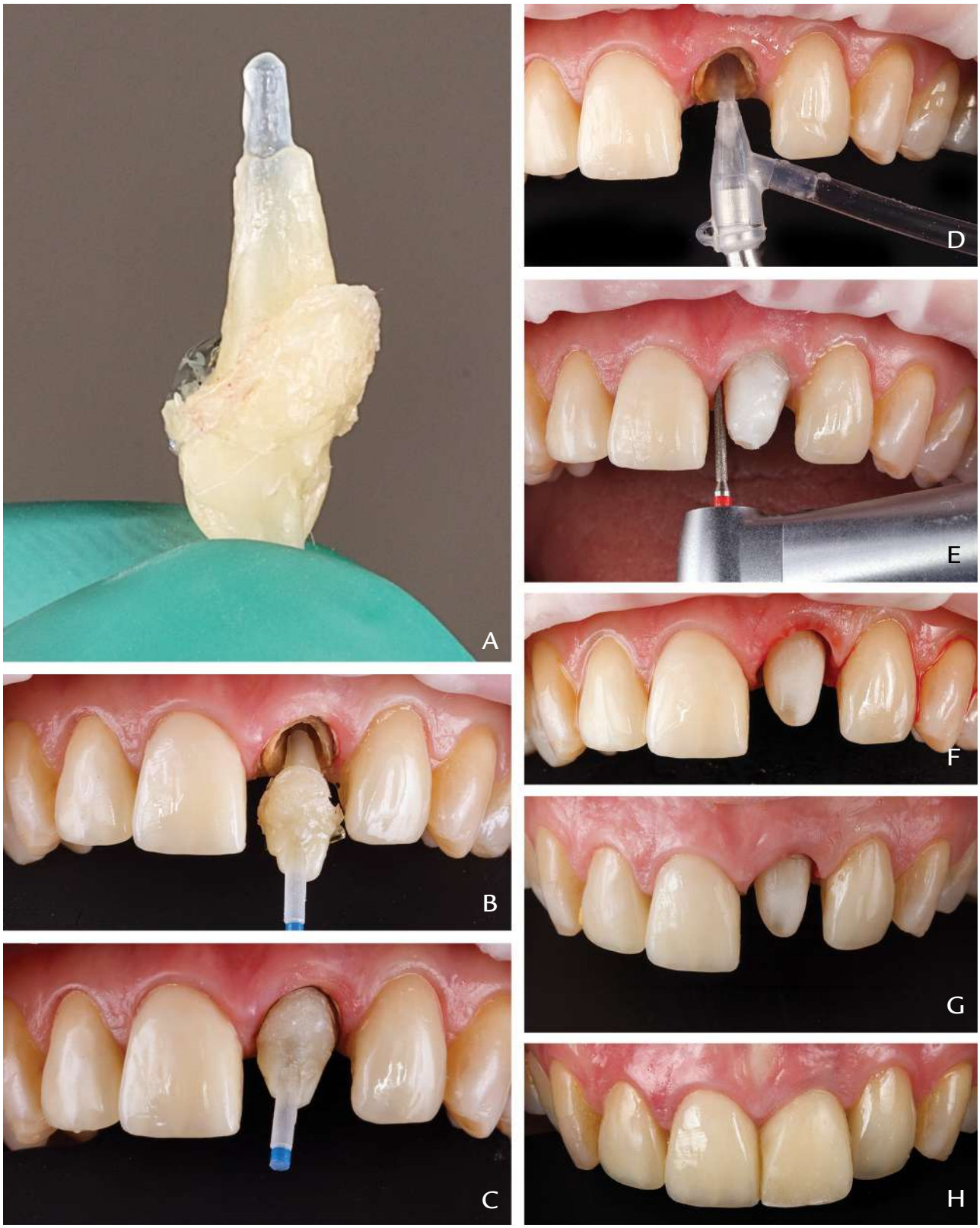


**Figure 3.** Fabrication of post-and-core foundation. A, B, Removal and polymerization of post extraorally. C, Verification of post-and-core structure. D, Airborne-particle abrasion of intracanal dentin with 50-µm $Al_2O_3$ (AquaCare; Velopex). E-H, Tooth preparation and placement of interim crown.

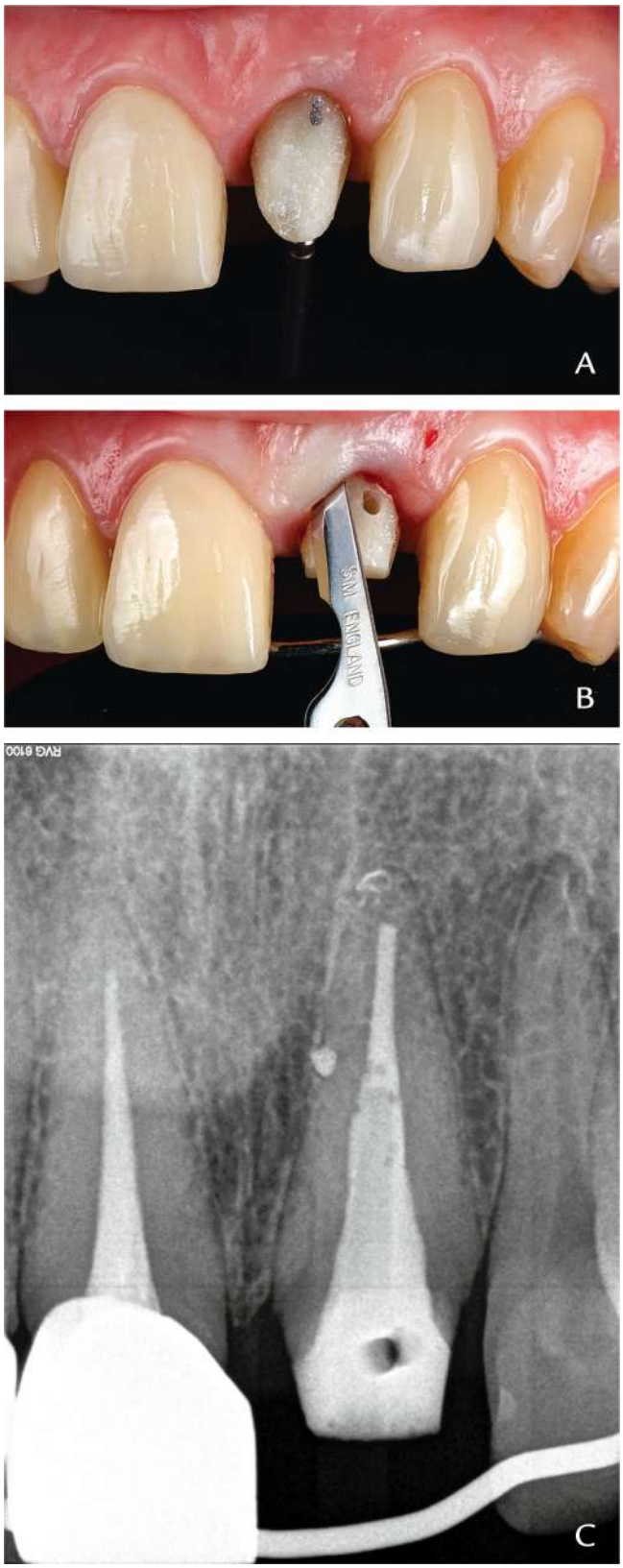


**Figure 4.** Post-and-core perforation. A, Transverse perforation of post-and-core structure with high-speed diamond rotary instrument. B, Circumferential supracrestal fiberotomy. C, Periapical radiograph.

contour similar to that of the adjacent tooth (Fig. 6G). The definitive zirconia restoration (Zirlux) layered with feldspathic porcelain was cemented with a self-adhesive universal resin cement (Calibra Universal bleach; Dentsply Sirona) (Fig. 7). A 0.5-mm band of polished zirconia was left in contact with the emergence profile. The patient was recalled at 4 weeks and then at 6, 12, and 24 months. Two years after the treatment, the restorative margin remained stable in relation to the gingival margin (Fig. 8). The patient was asymptomatic, and the periapical radiograph showed no signs of resorption or endodontic failure.

## DISCUSSION

Restoring a compromised tooth to ensure lasting periodontal health may require crown lengthening when it involves the STA. Margin restoration placement on a sound tooth structure is essential for long-term stability.[26,27] A 1.5- to 2-mm ferrule is deemed necessary to enhance the biomechanical function of the tooth.[15] The ferrule for a post-and-core retained crown is critical for preventing tooth or root fracture, possibly making the ferrule more important than the post material or the post's adhesion to the radicular dentin.[26] In addition, an extensive post space preparation was avoided by customizing the fiber glass post, thus preserving tooth structure, particularly in the pericervical region.

Surgical crown lengthening is the standard option for increasing clinical crown height. However, it involves several risks, such as sound periodontal attachment loss, concavities and molar furcation exposure, dentin hypersensitivity development, poor crown-to-root ratio, and an undesired nonesthetic gingival design.[19] Hence, bone resection may not always be feasible, particularly in anterior teeth where esthetic demands are an overriding factor.[28]

Surgical extrusion, or intra-alveolar transplantation, offers an alternative to improve restorability and reestablish the STA and entails intentionally displacing the remaining root more coronally within the socket.[29] However, the success of this technically sensitive procedure depends on atraumatic extraction while minimizing damage to the cementoblast layer and avoiding root fracture.[29] Orthodontic extrusion is effective for crown lengthening while restoring the STA, maintaining the alveolar bone, and achieving good esthetics.[18] Orthodontic extrusion may also be helpful for implant site development, eliminating or reducing periodontal infrabony defects and esthetic gingival margins.[30]

Among the orthodontic appliances used for forced orthodontic extrusion, fixed appliances are the standard treatment option[24]; however, both treatment and stabilization are long. This simplified approach with

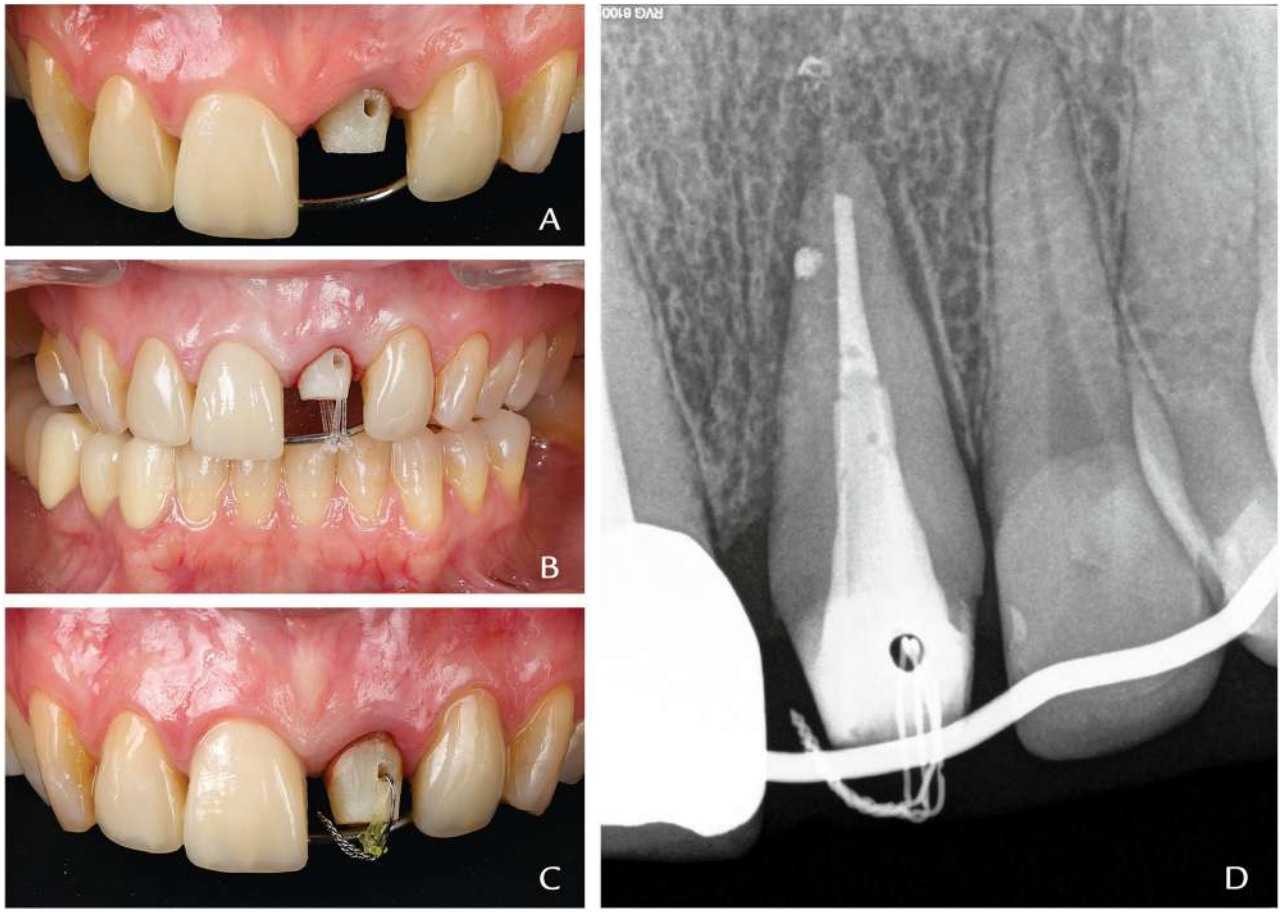


**Figure 5.** Placement of ligature system. A, Palatal bar placed perpendicular to long axis of tooth. B, Intracoronal elastic ligatures. C, Intracoronal metal ligatures. D, Periapical radiograph.

intracoronal elastic and metal ligatures shortens the procedure, minimizes forward clockwise movements during vertical extrusion, and preserves the buccal bone plate.[31] Once the tooth is coronal, the supracrestal structure is narrower in relation to the alveolus and the neighboring teeth. This problem and the lack of symmetry with the adjacent teeth were managed by preparing the tooth with the BOPT technique. This approach increases the volume of the coronal soft tissue by transforming the cervical part of the interim crown and does not weaken the horizontal preparation.[32]

Even though forced eruption is not routinely used, many clinicians recognize the relevance of clinical crown height in the long-term success of restorations and the amount of available hard and soft tissue for future implant placement. In addition, this versatile and minimally invasive technique offers a great deal of latitude and high predictability in managing both routine and complex multidisciplinary cases. However, evidence-based guidelines are lacking for case selection and management, and research regarding its possible complications is limited.

## SUMMARY

Forced orthodontic extrusion combined with the BOPT technique can be used to manage compromised teeth to provide a sound tissue margin for the definitive restoration. Furthermore, restoration after orthodontic eruption may be less invasive than prosthetic restoration after extraction.

## REFERENCES

1. Bruhnke M, Spies B, Beuer F, Neumeyer S. Forced orthodontic extrusion: a practical therapy method for apparently hopeless teeth? A case report. *Int J Prosthodont.* 2020;33:684–688.
2. Gargiulo A, Wentz F, Orban B. Dimensions and relation of the dentogingival junction in humans. *J Periodontol.* 1961;32:261–267.
3. Stankiewicz NR, Wilson PR. The ferrule effect: a literature effect. *Int Endod J.* 2002;35:575–581.
4. Ghezzi C, Brambilla G, Conti A, Dosoli R, Ceroni F, Ferrantino L. Cervical margin relocation: case series and new classification system. *Int J Esthet Dent.* 2019;14:272–284.
5. Sarfati A, Tirlet G. Deep margin elevation versus crown lengthening: biologic width revisited. *Int J Esthet Dent.* 2018;13:334–356.
6. Padbury Jr A, Eber R, Wang HL. Interactions between the gingiva and the margin of restorations. *J Clin Periodontol.* 2003;30:379–385.
7. Jepsen S, Caton JG, Albandar JM, et al. Periodontal manifestations of systemic diseases and developmental and acquired conditions: consensus report of Workgroup 3 of the 2017 World Workshop on the Classification of

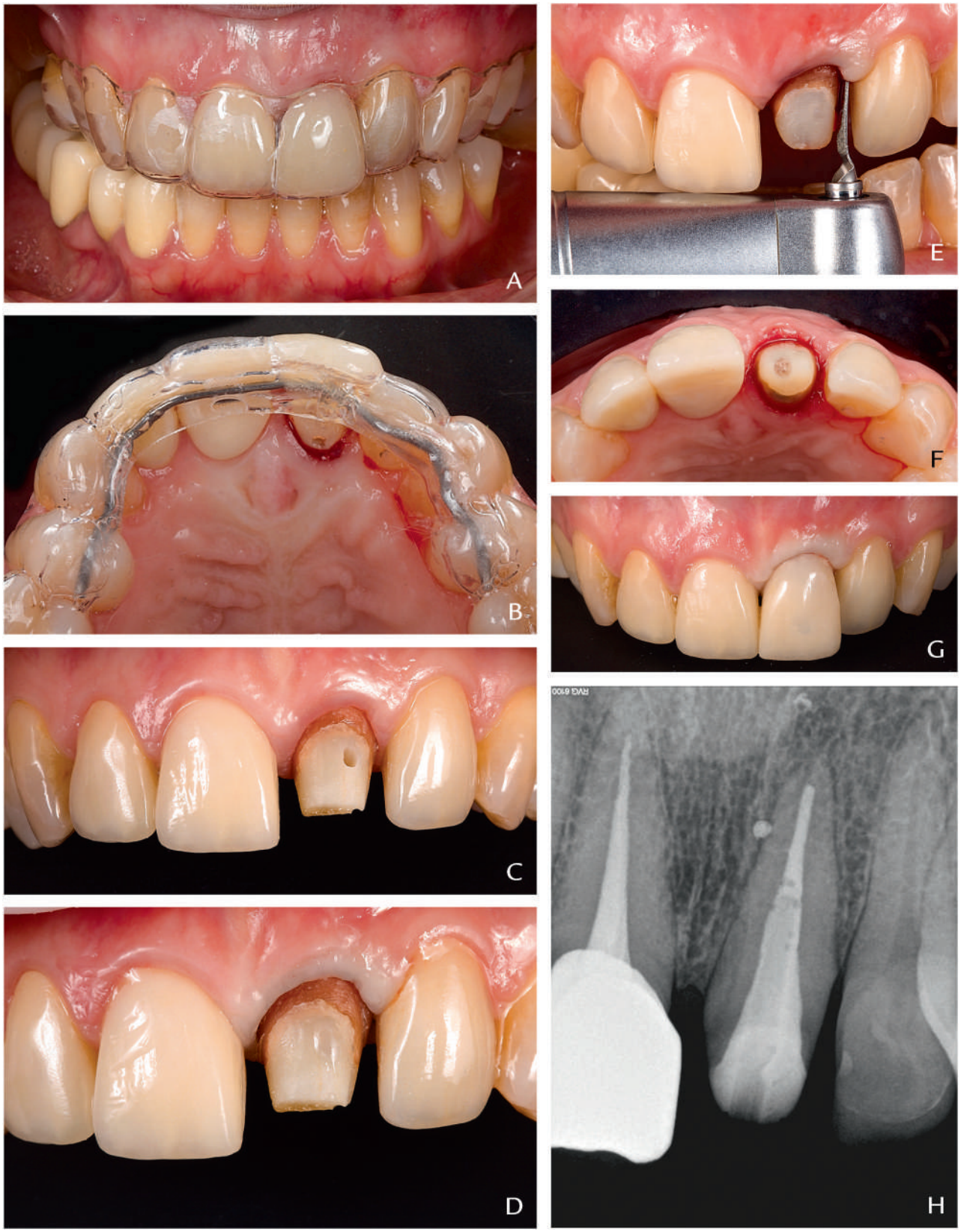


**Figure 6.** Biologically oriented preparation technique (BOPT). A, B, Essix-type removable retainer with composite resin laminate veneer. C, Ferrule achieved after orthodontic extrusion. D, Composite resin sealed perforation. E, F, Vertical preparation following BOPT. G, Relining and cementation of composite resin computer-aided design and computer-aided manufacture crown (Structure CAD; VOCO GmbH). H, Periapical radiograph.


**Figure 7.** Definitive zirconia restoration. A-C, Healing process and appearance of new emergence profile after 3 months. D, E, Zirconia restoration layered with feldspathic porcelain.

Periodontal and Peri-Implant Diseases and Conditions. *J Periodontol*. 2018;89: S237–S248.
8. Dietschi D, Spreafico R. Current clinical concepts for adhesive cementation of tooth-colored posterior restorations. *Pract Periodontics Aesthet Dent*. 1998;10: 47–54.
9. Ingber JS, Rose LF, Coslet JG. The "biologic width"–a concept in periodontics and restorative dentistry. *Alpha Omegan*. 1977;70:62–65.
10. Nevins M, Skurow HM. The intracrevicular restorative margin, the biologic width, and the maintenance of the gingival margin. *Int J Periodontics Restorative Dent*. 1984;4:30–49.
11. Wagenberg BD, Eskow RN, Langer B. Exposing adequate tooth structure for restorative dentistry. *Int J Periodontics Restorative Dent*. 1989;9:322–331.
12. Ross SE, Garguilo A. The surgical management of the restorative alveolar interface. *Int J Periodontics Restorative Dent*. 1982;2:8–31.
13. Deas DE, Moritz AJ, McDonnell HT, Powell CA, Mealey BL. Osseous surgery for crown lengthening: a 6-month clinical study. *J Periodontol*. 2004;75: 1288–1294.
14. Gegauff AG. Effect of crown lengthening and ferrule placement on static load failure of cemented cast post-cores and crowns. *J Prosthet Dent*. 2000;84:169–179.
15. Dietschi D, Duc O, Krejci I, Sadan A. Biomechanical considerations for the restoration of endodontically treated teeth: a systematic review of the literature - part 1. Composition and micro- and macrostructure alterations. *Quintessence Int*. 2007;38:733–743.
16. Kim SH, Tramontina V, Passanezi E. A new approach using the surgical extrusion procedure as an alternative for the reestablishment of biologic width. *Int J Periodontics Restorative Dent*. 2004;24:39–45.
17. Juloski J, Radovic I, Goracci C, Vulicevic ZR, Ferrari M. Ferrule effect: a literature review. *J Endod*. 2012;38:11–19.
18. González-Martín O, Solano-Hernandez B, González-Martín A, Avila-Ortiz G. Orthodontic extrusion: guidelines for contemporary clinical practice. *Int J Periodontics Restorative Dent*. 2020;40:667–676.
19. Fakhry A. Enhancing restorative, periodontal, and esthetic outcomes through orthodontic extrusion. *Eur J Esthet Dent*. 2007;2:312–320.
20. Heithersay GS. Combined endodontic-orthodontic treatment of transverse root fractures in the region of the alveolar crest. *Oral Surg Oral Med Oral Pathol*. 1973;36:404–415.
21. Ingber JS. Forced eruption. I. A method of treating isolated one and two wall infrabony osseous defects-rationale and case report. *J Periodontol*. 1974;45: 199–206.
22. Ingber JS. Forced eruption: part II. A method of treating nonrestorable teeth–periodontal and restorative considerations. *J Periodontol*. 1976;47: 203–216.


**Figure 8.** Two years after treatment. A, B, Clinical and radiographic views showing normal gingival architecture, no marginal bone loss, or periapical pathology.

23. Pontoriero R, Celenza Jr F, Ricci G, Carnevale G. Rapid extrusion with fiber resection: a combined orthodontic-periodontic treatment modality. *Int J Periodontics Restorative Dent.* 1987;7:30–43.
24. Hochman MN, Chu SJ, Tarnow DP. Orthodontic extrusion for implant site development revisited: a new classification determined by anatomy and clinical outcomes. *Semin Orthod.* 2014;20:208–227.
25. Loi I, Di Felice A. Biologically oriented preparation technique (BOPT): a new approach for prosthetic restoration of periodontically healthy teeth. *Eur J Esthet Dent.* 2013;8:10–23.
26. Naumann M, Schmitter M, Frankenberger R, Krastl G. "Ferrule comes first. Post is second!" Fake news and alternative facts? A systematic review. *J Endod.* 2018;44:212–219.
27. Zarow M, Ramírez-Sebastià A, Paolone G, de Ribot Porta J, Mora J, Espona J, et al. A new classification system for the restoration of root filled teeth. *Int Endod J.* 2018;51:318–334.
28. Pham HT, Nguyen PA, Pham TAV. Periodontal status of anterior teeth following clinical crown lengthening by minimally traumatic controlled surgical extrusion. *Dent Traumatol.* 2018;34:455–463.
29. Plotino G, Abella Sans F, Duggal MS, et al. Clinical procedures and outcome of surgical extrusion, intentional replantation and tooth autotransplantation - a narrative review. *Int Endod J.* 2020;53:1636–1652.
30. Salama H, Salama M, Garber D. Guidelines for aesthetic restorative options and implant site enhancement: the utilization of orthodontic extrusion. *Pract Proced Aesthet Dent.* 2002;14:125–130.
31. Casaponsa J, de Ribot D, Roig M, Abella F. Magnetic extrusion technique for restoring severely compromised teeth: a case report. *J Prosthet Dent.* 2022;127:542–549.
32. Agustín-Panadero R, Serra-Pastor B, Loi I, Suárez MJ, Pelaez J, Solá-Ruíz F. Clinical behavior of posterior fixed partial dentures with a biologically oriented preparation technique: a 5-year randomized controlled clinical trial. *J Prosthet Dent.* 2021;125:870–876.

**Corresponding author:**
Dr Francesc Abella
Dentistry Faculty
Universitat Internacional de Catalunya
C/Josep Trueta s/n
Sant Cugat del Vallès 08195
SPAIN
Email: franabella@uic.es

**Acknowledgments**
The authors thank Manuel Mínguez Alcarriá for collaboration during the prosthetic part of the treatment and Mark Lodge for language support in revising this paper.


https://doi.org/10.1016/j.prosdent.2022.06.020